

Ranula Unveiled: A Case Report and Management Approach

Dr. Shyam Sunder Singh, MD (Hom) – Professor, Dept. of Practice of Medicine, Rani Dullaiya Smriti HMC, Bhopal.

Ph. 9425027612. Website: <http://drsinghclinic.com>

A 4-year-old girl presented with nodulated tumors on her tongue, which were devoid of any pain. Based on her symptoms, she was identified to have a scrofulous

diathesis, as depicted in Figure 1. Treatment was commenced on 11th April 2019. The prescribed medication was Galium aparine-1X, administered as 10 drops twice daily for a duration of 10 days. During the final visit on 23rd April 2019, significant improvement was observed in all symptoms, as illustrated in Figure 2.

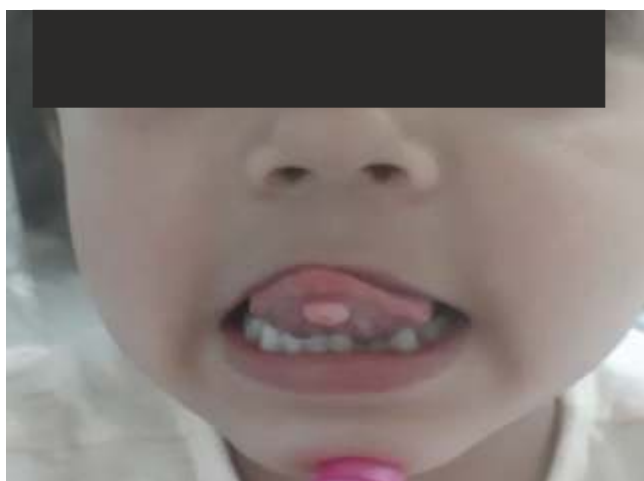


Figure 1. Before treatment




Figure 2. After treatment

Exploring Pyoderma: A Clinical Case Report*

A female patient sought medical attention for an inflamed patch on her left cheek. She described experiencing intense burning, itching, a sensation of heat, and pain upon touching the affected area, as shown in Figure 1. The prescribed treatment involved Antimonium crudum 6 CH, with the patient instructed to take 4 pills three times a day for a duration of 5 days. At the final visit, notable improvement in symptoms was observed, as depicted in Figure 2.

**Case by the previous author*

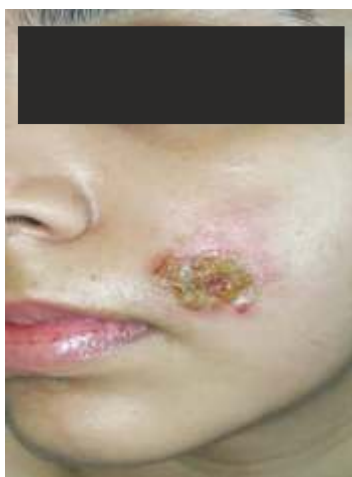

Figure 1. Before treatment

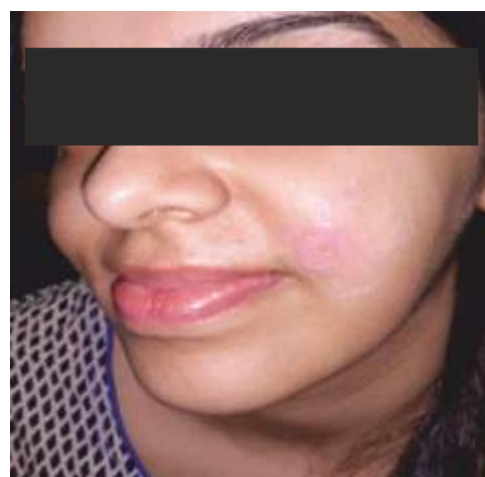

Figure 2. After treatment